

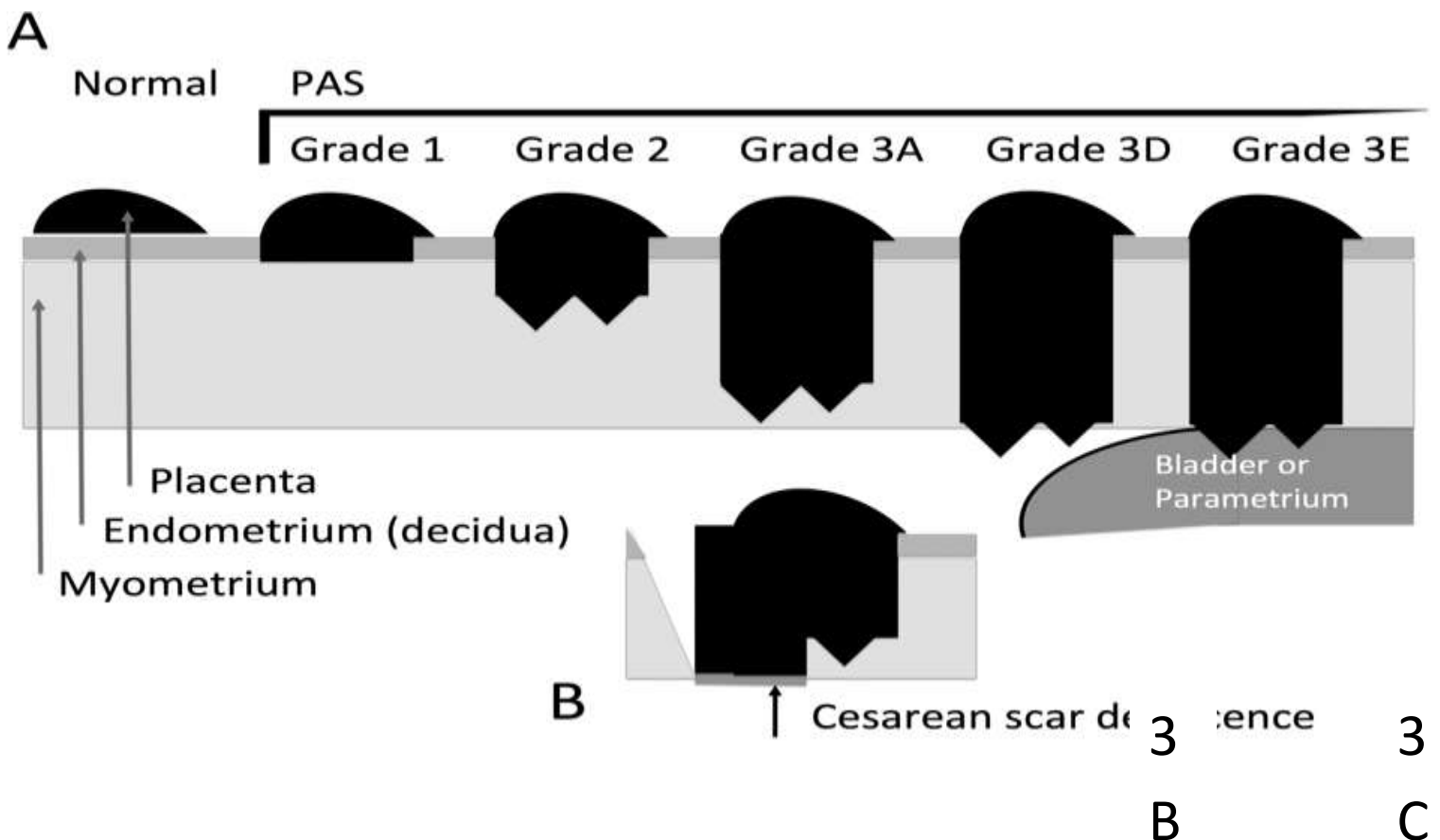
Placenta Accreta Spectrum

BACKGROUND

Placenta Accreta Spectrum (PAS) with attachment to the myometrium is becoming increasingly common, largely as a result of the increasing cesarean rate.

| <u>Prior cesarean deliveries</u> | <u>No previa</u> | <u>Placenta previa</u> |
|----------------------------------|------------------|------------------------|
| 1 | .03% | 3.3% |
| 2 | 0.2 | 11 |
| 3 | 0.1 | 40 |
| 4 | 0.8 | 61 |
| 5 | 0.8 | 67 |
| 6 | 4.7 | 67 |

The FIGO classification grades PAS through combination of clinical and histological data:
 -Grades 1-3, with grade 3 distinguishing between 3a, b, and c



Nevertheless, as demonstrated in the table below, placenta accreta is most commonly seen in the setting of placenta previa in women with multiple prior cesareans:

| <u>Prior cesarean deliveries</u> | <u>No previa</u> | <u>Placenta previa</u> |
|----------------------------------|------------------|------------------------|
| 1 | .03% | 3.3% |
| 2 | 0.2 | 11 |
| 3 | 0.1 | 40 |
| 4 | 0.8 | 61 |
| 5 | 0.8 | 67 |
| 6 | 4.7 | 67 |

COMPLICATIONS

The following complications need to be anticipated in women with Placenta Accreta Spectrum:

- Life-threatening hemorrhage with need for large volume transfusion
- Hysterectomy
- Damage to adjacent organs (bladder, ureters, bowel)

COMPLICATIONS

The following complications need to be anticipated in women with abnormal placentation:

- Life-threatening hemorrhage with need for large volume transfusion
- Hysterectomy
- Damage to adjacent organs (bladder, ureters, bowel)
- Postoperative bleeding and repeat surgery
- Coagulopathy (dilutional or consumptive)
- Adult respiratory distress syndrome (ARDS)
- Thromboembolism and amniotic fluid embolism
- Multiorgan failure and maternal death

DIAGNOSIS

Ultrasound is the usual antenatal method by which placenta accreta is diagnosed. Sonographic findings associated with abnormal placentation include:

- loss of the hypoechoic retroplacental zone
- multiple vascular placental lakes (“Swiss cheese” or “moth-eaten” appearance)
- numerous coherent blood vessels bridging the placental-myometrial (or serosal), or myometrial-bladder, interface, as seen with color Doppler
- retroplacental myometrial thickness <1 mm

Two or more of the above criteria are sufficient to raise suspicion of the diagnosis and consultation should be sought. The poorest predictive value is associated with loss of the hypoechoic retroplacental zone. The best predictive value is associated with abnormal vasculature at the myometrial-bladder interface, especially when corroborated by 3-D power Doppler.

Ultrasound, with color Doppler, has a sensitivity of 89-97% and a specificity of 92-98% for the diagnosis of abnormal placentation. Use of MRI has not been demonstrated to improve management or outcome.

PREOPERATIVE MANAGEMENT

Women with known Placenta Accreta Spectrum should be transferred to, and remain in, Anchorage as soon as the diagnosis is established. Hospitalization is not necessarily indicated in women who are not bleeding, as long as reliable transportation to hospital is assured. Women should be aware that the recommended treatment, hysterectomy, will result in permanent sterility. Discussion of conservative management, if desired by the patient, should be documented.

If life-threatening maternal hemorrhage does not occur prior, elective late preterm (at 34 weeks) cesarean delivery, with planned hysterectomy with the placenta in situ, has been demonstrated to result in the best maternal and infant outcomes. Betamethasone administration at least 48 hours prior to scheduled surgery should be performed for fetal benefit.

Leaving the placenta in situ, with subsequent methotrexate treatment, has been associated with delayed life-threatening hemorrhage, infection, as well as delayed hysterectomy, and is not recommended.

Consultation with Anesthesiology prior to scheduled surgery is essential. General anesthesia, not neuraxial anesthesia, is the most appropriate choice. At least two large bores IV lines should be in place, and consideration should be given to central venous pressure and intra-arterial pressure monitoring. Use of compression thromboprophylaxis devices and warming blankets should be routine.

Prepare to use the ANMC Obstetric Hemorrhage Guideline

Notification of the Blood Bank as per the ANMC Obstetric Hemorrhage Guideline is critical as intraoperative blood loss of 2 to 10 liters may be anticipated, and transfusion of multiple units of packed red blood cells, as well as other blood products, including fresh frozen plasma (FFP) and platelets, is to be anticipated. Blood should ideally be available in the operating suite at the time of incision.

Consideration of additional surgical services (gynecologic oncology, urology*, vascular surgery) may be prudent. At least two experienced obstetric surgeons should be scrubbed in for known abnormal placentation cases. The literature is divided on the value of preoperative ureteral stent placement, and intravascular catheter access (for internal femoral artery balloon occlusion or embolization), and these modalities are not currently considered routine.

If a woman is suspected of having placenta accreta and she refuses blood products, then consider pre-operative notification or consultation with Interventional Radiology.

*If there is a high index of suspicion for accreta, consider obtaining a cystoscopy by Urology pre-operatively. This can be performed as an out-patient prior to surgery, or in the OR just before one starts the case.

INTRAOPERATIVE MANAGEMENT

A midline incision will facilitate the best exposure and is the preferred incision type for this situation.

“Frog-leg” position, with the hips flexed and abducted, can be considered, in order that the degree of vaginal blood loss may be more adequately evaluated, and so that a third assistant may more easily be positioned below.

The uterine incision should be made in the upper portion of the uterus, away from the placental insertion in the lower uterine segment. The fetus should be extracted from the fundal region of the uterus. The placental portion of the cord should be ligated, then replaced back into the uterus. The hysterotomy should be closed in a single layer, then proceed with hysterectomy.

It is suggested that the major vascular pedicles (adnexal and uterine artery pedicles) should be isolated and cross-clamped as rapidly as possible, without suture ligation, until the uterine blood supply has been interrupted.

After uterine devascularization has been accomplished, if bladder involvement is suspected, intentional cystotomy should be considered in order to evaluate the extent of invasion. This will lessen the possibility of damage to the bladder as the hysterectomy proceeds. Depending on the degree of invasion, significant bleeding can occur with attempts to dissect the bladder, and consideration of leaving a portion of the involved bladder attached to the uterus may be necessary, as long as the trigone is not involved.

Subtotal hysterectomy, leaving the cervix, may be considered, but has been associated with persistent hemorrhage, and, because of placental cervical implantation, is usually precluded.

Prompt blood product transfusion is usually needed. Recent data from the Iraq conflict have demonstrated that, in the setting of massive hemorrhage, giving FFP and platelets liberally, in a 1:1 or 1:2 ratio with packed cells, was associated with less coagulopathy, and the best outcomes. The use of cell-saver autotransfusion can be considered if available.

Prepare for possible X-ray guided pelvic artery embolization with on call IR notification. If insufficiently stable to be transported to IR, then pelvic pressure packing is preferred for diffuse non-arterial bleeding that is not amenable to surgical control, at least until hemodynamic stabilization and correction of coagulopathy can be accomplished.

Internal iliac (hypogastric) artery ligation is associated with a high rate of failure to control uterine bleeding, as well as a high incidence of damage to the ureter and nearby vascular structures, and is not currently recommended as a primary means of achieving pelvic hemostasis.

Not attempting to remove the placenta, rapid uterine devascularization, and liberal use of FFP, will usually prevent the situation where uncontrollable bleeding and coagulopathy supervene, but may not always be possible in the emergent cesarean with an unrecognized abnormal placentation.

POSTOPERATIVE MANAGEMENT

Postoperative problems that may require ICU care include:

- persistent hypotension secondary to inadequate blood and volume replacement
- persistent coagulopathy
- pulmonary edema or ARDS
- renal dysfunction, particularly acute tubular necrosis (ATN), and unrecognized urinary tract injury
- Sheehan syndrome (hyponatremia is the earliest sign)
- pulmonary embolism
- postoperative infectious morbidity

REFERENCES

1. Postpartum hemorrhage. Practice Bulletin No. 183. American College of Obstetricians and Gynecologists. *Obstet Gynecol* 2017;130:e168–86.
2. Placenta accreta spectrum. Obstetric Care Consensus No. 7. American College of Obstetricians and Gynecologists. *Obstet Gynecol* 2018;132:e259–75. (Re-affirmed 2021)
3. Leduc D, Senikas V, Lalonde AB. No. 235-Active Management of the Third Stage of Labour: Prevention and Treatment of Postpartum Hemorrhage. *J Obstet Gynaecol Can.* 2018 Dec;40(12):e841-e855.

4. Royal College of Obstetricians and Gynaecologists. Placenta Praevia, Placenta Praevia Accreta and Vasa Praevia: Diagnosis and Management, 4th Edition. (Green-top Guideline No. 27a) 2018 (Reviewed June 17, 2022) (Accessed 11/19/22)
5. Neilson JP. Interventions for suspected placenta praevia. Cochrane Database of Systematic Reviews 2003, Issue 2. Art. No.: CD001998. (Accessed 11/19/22)
6. Belfort MA. Placenta accreta. Publications Committee, Society for Maternal-Fetal Medicine Am J Obstet Gynecol 2010; 203:430-9.
7. Silver RM, et al. Maternal morbidity associated with multiple repeat cesarean deliveries. Obstet Gynecol 2006; 107:1226-32.
8. O'Brien JM, et al. The management of placenta percreta: conservative and operative strategies. Am J Obstet Gynecol 1996; 175:1632-8.
9. Eller AG, et al. Optimal management strategies for placenta accreta. BJOG 2009; 116:648-54.
10. Comstock CH. Antenatal diagnosis of placenta accreta: a review. Ultrasound Obstet Gynecol 2005; 26:89-96.
11. Warshak CR, et al. Accuracy of ultrasonography and magnetic resonance imaging in the diagnosis of placenta accreta. Obstet Gynecol 2006; 108:573-81.
12. Shih JC, et al. Role of 3-D power Doppler in the antenatal diagnosis of placenta accreta: comparison with gray-scale and color Doppler techniques. Ultrasound Obstet Gynecol 2009; 33:193-203.
13. Cali G, et al. Morbidly adherent placenta: evaluation of ultrasound diagnostic criteria and differentiation of placenta accreta from percreta. Ultrasound Obstet Gynecol 2013; 41: 406-12.

Revised 11/19/22 njm
Reviewed 10/31/20 njm
Revised 7/6/18 njm
Revised 4/23/16njm
Revised 2/7/14njm
Reviewed 9/21/11njm